



# Use of the Middle Colic Vein for Liver Cell Transplantation in Infants and Small Children

J. Meyburg, F. Hoerster, J. Weitz, G.F. Hoffmann, and J. Schmidt

---

## ABSTRACT

**Introduction.** Because it is less invasive, intraportal liver cell transplantation (LCT) is an interesting alternative to whole organ transplantation. The inferior mesenteric vein is usually chosen for portal vein access. However, anatomical variations are common in children, so we investigated catheter insertion into the middle colic vein.

**Patients and Methods.** Three children (3 weeks to 3 years; 3 to 14 kg) underwent LCT in our center for acute liver failure or severe neonatal urea cycle disorders. Small 4.2-French Hickman lines were surgically introduced into the middle colic vein and advanced to the portal vein stem. The patients received repetitive infusions of liver cells over a period of 4–11 days.

**Results.** Catheter insertion was feasible and tolerated well despite the poor clinical condition of 1 patient and the metabolic instability in the other 2 patients. Blood could be drawn from all catheters, and measurement of portal vein pressure was possible in 2 children. The patient with acute liver failure died after 11 days from complications of the underlying disease. In the other 2 children, portal vein catheters stayed patent for several months.

**Conclusions.** The middle colic vein can be recommended for placement of intraportal LCT catheters even in small and critically ill infants.

---

**L**IVER cell transplantation (LCT) is under investigation for a variety of hepatic-based disorders, including acute liver failure and inborn errors of metabolism. In infants and small children, vascular access to the portal vein system for cell infusion is challenging. We describe the use of small Hickman catheters inserted into the middle colic vein, which was feasible in 3 small and critically ill children treated in our center.

## PATIENTS AND METHODS

Between November 2006 and February 2007, 3 children underwent LCT. One patient (3 weeks/3 kg) was treated for acute liver failure caused by neonatal herpes infection; 2 patients suffered from severe neonatal urea cycle disorders (10 weeks/6 kg and 3 years/14 kg). The first 2 patients had contraindications for orthotopic liver transplantation (OLT); in the third patient, OLT was declined by the parents. Median abdominal incision was done under general anaesthesia. The greater omentum was dissolved from the transverse colon to get access to the bursa omentalis. After identification of the middle colic vein, a 4.2-French Hickman catheter was cut diagonally at the tip, introduced into the vein, and advanced toward the portal vein stem. After its correct position was verified using

intraoperative contrast imaging, the catheter was fixated at the transverse mesocolon. The catheters were flushed continuously with a saline solution containing 2 U/mL heparin.

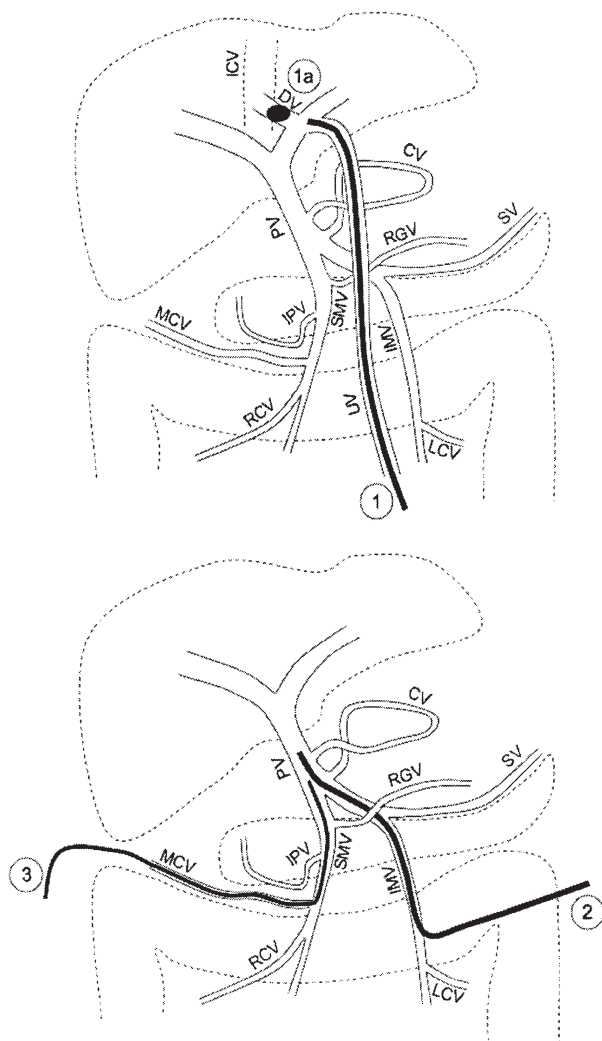
## RESULTS

In all 3 children, catheter placement was successful although the diameter of the middle colic vein was only about 1 mm. Contrast imaging showed undisturbed flow into the portal vein and its branches. Blood could be aspirated in all cases. In 1 patient, the catheter could be advanced only about 5 cm, whereas more distal catheter positions allowed measurement of the portal vein pressure in the other 2 children. All catheters stayed patent during the application period of 4–11 days. The infant with acute liver failure died from hemophagocytic histiolymplocytosis as a complication

---

From the Department of General Pediatrics, University Children's Hospital, and Department of General and Visceral Surgery, University Clinic, Heidelberg, Germany.

Address reprint requests to Jochen Meyburg, University Children's Hospital, Im Neuenheimer Feld 150, 69120 Heidelberg, Germany. E-mail: [jochen.meyburg@med.uni-heidelberg.de](mailto:jochen.meyburg@med.uni-heidelberg.de)



**Fig 1.** Vascular access to the portal vein system. (Upper panel) Cannulation of the umbilical vein (1) with additional balloon catheter (1a) blocking the Ductus venosus in neonates. (Lower panel) Surgical access using the inferior mesenteric vein (2) or the middle colic vein (3). Abbreviations: ICV, inferior caval vein; DV, ductus venosus; PV, portal vein; CV, coronary vein; RG, right gastroepiploic vein; SV, splenic vein; SMV, superior mesenteric vein; IPV, inferior pancreaticoduodenal vein; IMV, inferior mesenteric vein; MCV, middle colic vein; RCV, right colic vein; and LGV, left colic vein.

of the herpes infection. The 2 metabolic patients experienced metabolic stabilization to some degree and were discharged with the portal vein catheters. In 1 of these children, repetition of LCT was considered after 6 months, but contrast imaging showed dislocation of the catheter at that time. In both children, the portal vein catheters could

be easily removed without surgical intervention or local bleeding.

## DISCUSSION

Since the first clinical application of LCT in humans 1993, several methods of portal vein access have been described. In patients with acute liver failure, repetitive cell infusions are uncommon, thus a transhepatic approach is commonly used.<sup>1</sup> Similar considerations are made in cases of Crigler-Najjar syndrome.<sup>2</sup> In patients with metabolic diseases, repetitive applications bear the least risk for portal vein thrombosis or extrahepatic shunting of hepatocytes. Severe urea cycle disorders, which may be regarded as a model disease for LCT, usually present during the first days of life. As long as the umbilical vein is patent, it can be elegantly used for portal vein access (Fig 1). During LCT, the ductus venosus has to be blocked with a second balloon catheter to prevent shunting of the cells into the caval vein.<sup>3,4</sup> Our 3 children were all treated after the first postnatal week, therefore, surgical catheter insertion was necessary (Fig 1). In the literature, the inferior mesenteric vein is almost exclusively described for portal vein access.<sup>5</sup> Because it can be easily accessed, the middle colic vein may be a good alternative. It is frequently used for catheter placement in cases of portal vein thrombosis, when local thrombolysis is required prior to OLT. Although more than 1 middle colic vein may be present, anatomic variations are limited compared with other tributaries of the portal vein.<sup>6</sup> Our patients all had singular middle colic veins that could be easily identified. Although small in diameter, appropriate Hickman catheters could be introduced and advanced into the portal vein stem. Because it was technically feasible and well tolerated in our critically ill patients, we can recommend this approach for children treated after the neonatal period.

## REFERENCES

1. Schneider A, Attaran M, Meier PN, et al: Hepatocyte transplantation in an acute liver failure due to mushroom poisoning. *Transplantation* 82:1115, 2006
2. Fox IJ, Chowdhury JR, Kaufman SS, et al: Treatment of the Crigler-Najjar syndrome type I with hepatocyte transplantation. *N Engl J Med* 338:1422, 1998
3. Horslen SP, McCowan TC, Goertzen TC, et al: Isolated hepatocyte transplantation in an infant with a severe urea cycle disorder. *Pediatrics* 111:1262, 2003
4. Mitry RR, Dhawan A, Hughes RD, et al: One liver, three recipients: segment IV from split-liver procedures as a source of hepatocytes for cell transplantation. *Transplantation* 77:1614, 2004
5. Darwish AA, Sokal E, Stephenne X, et al: Permanent access to the portal system for cellular transplantation using an implantable port device. *Liver Transpl* 10:1213, 2004
6. Yamaguchi S, Kuroyanagi H, Milsom JW, et al: Venous anatomy of the right colon: precise structure of the major veins and gastrocolic trunk in 58 cadavers. *Dis Colon Rectum* 45:1337, 2002